

# Treatment of Young Athletes with Spine Injuries



**North American Spine Society  
Public Education Series**

# Treatment of the Young Athlete

Although not common, low back injuries can occur in young athletes who participate in sports. Though injuries that cause back pain are not the most common cause of injury in the young athlete, they can cause frustration. Most athletic injuries to the back are sprains of the ligaments or strains of the muscles. However, several more serious conditions can have symptoms similar to a routine sprain or strain. Many injuries occur after repetitive overuse of the structures of the spine. Therefore, proper treatment of a young athlete always includes a good physician evaluation with imaging studies when necessary.

## **Muscular Strains and Ligament Sprains**

These are the most common injuries that cause back pain in the young athlete. They can be caused by athletic overuse, improper body mechanics and technique, lack of proper conditioning, insufficient stretching, as well as trauma. The athlete will complain of back pain with activity and will feel relief with rest.

Initial treatment may require a period of rest, removing the athlete from sports participation. Treatments may include medication and special exercise. Ice can be used along with pain medications, which should be used sparingly. In addition, other measures to control pain and restore motion are commonly used. Initially, ice and medications such as nonsteroidal antiinflammatories can be used. For persistent symptoms, particularly those associated with muscle spasm, heat may also be very helpful.

As pain decreases, the injured athlete should be shown proper exercise to assist recovery. An exercise program can be very beneficial to improve

flexibility and strength of the appropriate muscles for athletic performance as well as to help decrease risk for another similar injury. It is also important to maintain aerobic conditioning during treatment for back pain. Aerobic exercise needs to be tailored to the athlete and performed as pain allows. The repetitive overuse of the spine (particularly rotation) should be avoided, at least initially. Before being released to return to play, sport-specific exercises that mimic activities of athletic competition are often included in the exercise program. It is also always important to evaluate and correct poor technique and mechanics that may have predisposed the athlete to the initial injury.

### **Spondylolysis and Spondylolithesis**

Defects of a vertebra's pars interarticularis (spondylolysis) and the slippage of one vertebra in relation to another vertebra (spondylolisthesis) are common causes of back pain in the young athlete. (See the NASS Patient Education Brochure on Spondylolysis and Spondylolisthesis for a complete explanation of these conditions.)

These injuries are often seen in athletes who participate in sports that require twisting and hyperextension of the spine, such as in gymnas-



## Treatment of the Young Athlete *Continued...*

tics. The athlete usually complains of pain that worsens when arching the back. The physician must be alert because these injuries often appear to be a sprain or strain. X-ray images are often normal and special imaging studies such as bone scan and CT scan may be required to confirm the diagnosis.

Recovery requires a period of relative rest, ice, medication and specific exercises. It is important that inflexible muscles are stretched and the trunk muscles strengthened. In some cases, bracing may be necessary to allow for proper healing. In acute cases of spondylolysis, special stabilization training may be prescribed. In milder cases, progression back to sports is similar to that for sprains and strains.

A few special considerations are important in an athlete who has developed a spondylolithesis. Athletes with 50% or less forward slippage can usually return to all sporting activities after pain resolves and appropriate rehabilitation has been completed. Athletes with 50% or greater forward slippage are encouraged to participate in less aggravating sports. Also, athletes with a spondylolithesis should be monitored every six months for progressive slippage as they go through any adolescent growth spurt.



### **Scheuermann's Disease (Juvenile Kyphosis)**

Another common problem seen in the young athlete with back pain is juvenile kyphosis. Pain associated with this occurs during puberty and is in the mid-back, rather than the low back. The athlete demonstrates a roundback deformity that worsens to a "dome" appearance of the back

with bending forward. Diagnosis is made by X-ray examination that shows at least three consecutive vertebra show a wedging of five degrees or more.

Treatment in most cases is aimed at relieving symptoms. Extension-based back exercises and postural exercises are essential. These can provide significant symptomatic relief, but it is important to note that the structural curve cannot be corrected with these exercises. For curves of 50 degrees or greater, bracing can be helpful if the athlete is able to tolerate wearing the brace. For athletes with severe curves who continue to have debilitating pain despite bracing, surgical correction and stabilization may be required. It is important to note that this may limit the athlete's ability to return to their given sport. As with all spine-based injuries, a complete rehabilitation program is essential prior to return to athletic competition.

### **Disc Injury**

Though a common cause of back pain in the adult population, disc injury is relatively uncommon in the young athletic population. Back pain from a disc injury may or may not be associated with sciatica (pain that shoots down the leg). A careful






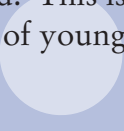
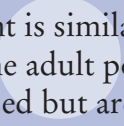




## Treatment of the Young Athlete *Continued...*

history and examination is very important in determining if a disc problem may be the cause of the athlete's complaints. MRI can also be helpful in determining if a disc is a cause for the pain and to rule out other potential causes that may mimic disc injury in an adolescent.

Treatment is similar to treatment of a disc herniation in the adult population. Epidural injections can be used but are not necessary in most cases. If symptoms do not improve with a comprehensive rehabilitation program, then surgery may be indicated. This is necessary only in a small percentage of young athletes with disc injury.



Notes





## DISCLAIMER

This brochure is for general information and understanding only and is not intended to represent official policy of the North American Spine Society. Please consult your health care provider for specific information about your condition.

© 2003-2013 North American Spine Society